

## Unique Cervical Injuries

“Lessons Learned”

Andrew Dossett, MD  
WB Carrell Clinic, Dallas  
March 28, 2010

## Experience

## Brain Burn

Singes Cerebral  
Cortex

## Unexplained Radiculopathy

Persistent pain,  
numbness and  
weakness in the arm

## MRI

- Very good anatomic detail
- No radiation
- Screening Test (non-invasive)

## MRI Pitfalls

- Fair bone detail
- Overstates stenosis
- Signal Void in Neuroforamen
- Claustrophobic

## MRI Pitfalls

- Signal Void
- “Flow Artifact” from foraminal artery and vein
- Misses some Foraminal Disc Herniations

## IV Contrast CT Scan

- Excellent bone detail
- Highlights neuroforaminal pathology
- Contrast fills neuroforaminal vessels

## Spring Training 2003

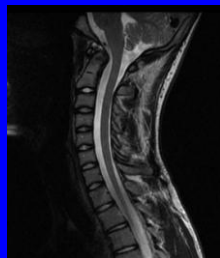
Surprise, AZ

## Professional Shortstop

- New onset left triceps weakness
- Difficulty swinging bat
- Highest paid athlete in the world (154K/ game)

## MRI

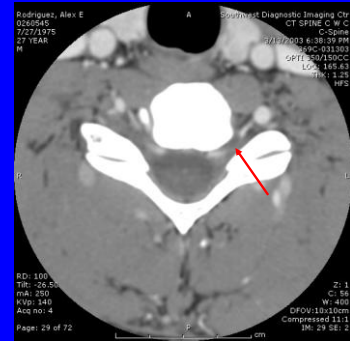
- Expect left C7 Pathology
- “Nada”
- Normal MRI



**Never Let a Test  
Stand Between  
You and the  
Diagnosis**

## Look For the Foraminal Disc

IV Contrast CT Scan



## Follow Up

- Steroid injections
- □□PT
- Had weak triceps all season
- .298 avg., 118 RBI, 47 HR
- Won his first AL MVP

## Take Home Lessons

- IV Contrast CT scan for unexplained radiculopathy
- Never let a test stand between you and a diagnosis

## THANK YOU

